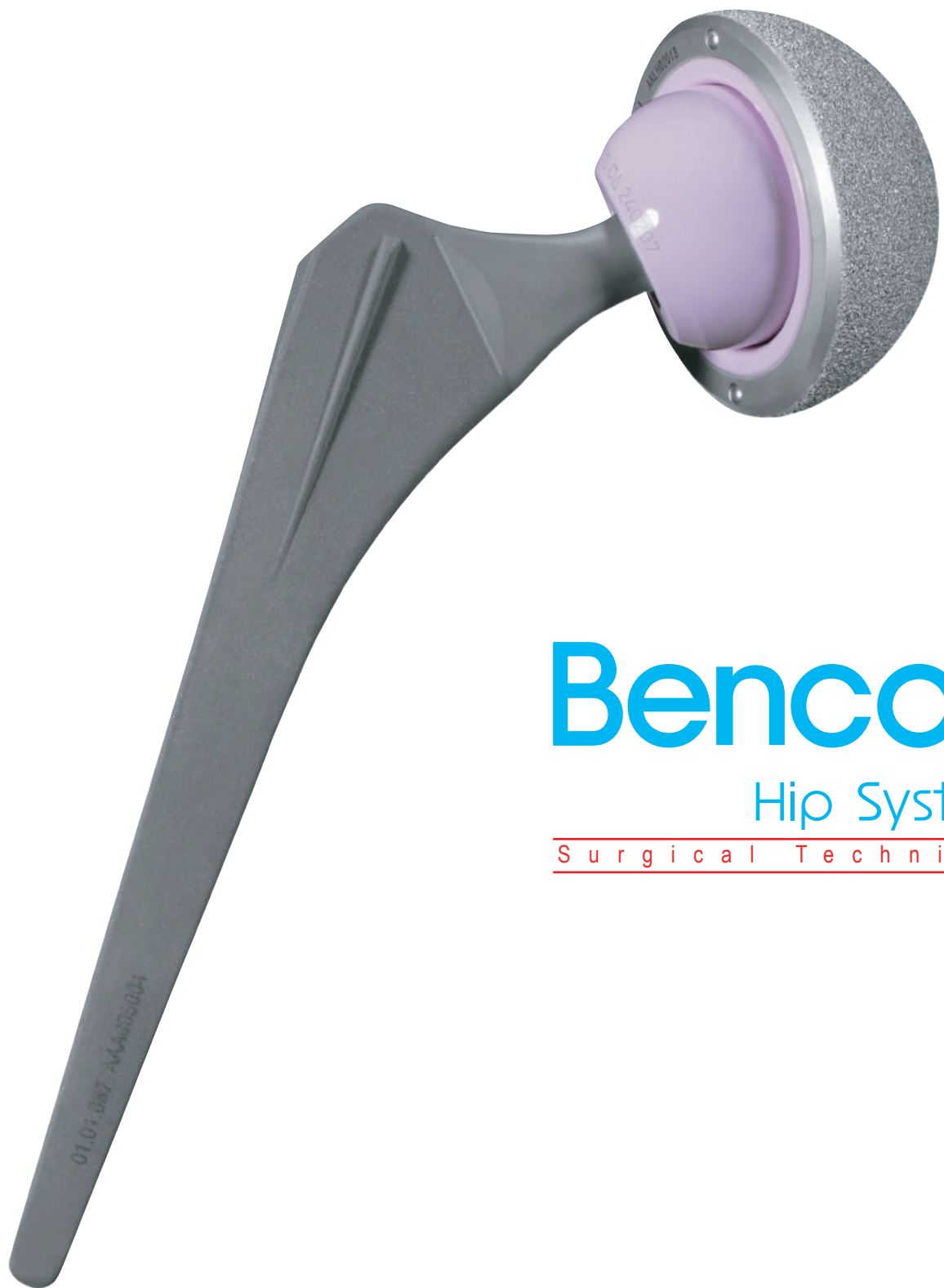



Bencox

Hip System

Surgical Technique

Bencox Hip System

Table of Contents

Surgical Technique

I. X-Ray Templating and Preoperative Planning 03

II. Patient positioning and Surgical Approach 04

1. Posterolateral Approach

2. Lateral Approach

III. Surgical Procedures

1. Femoral Neck Resection 05

2. Acetabular Exposure and Reaming 06

3. Positioning of the Acetabular Cup Trialing 06

4. Positioning and Impacting the Cup 07

5. Liner Insertion 08


6. Canal Preparation 09

7. Rasping 09

8. Femoral Stem Insertion and Trial Reduction 10

9. Insertion of Femoral Head 11

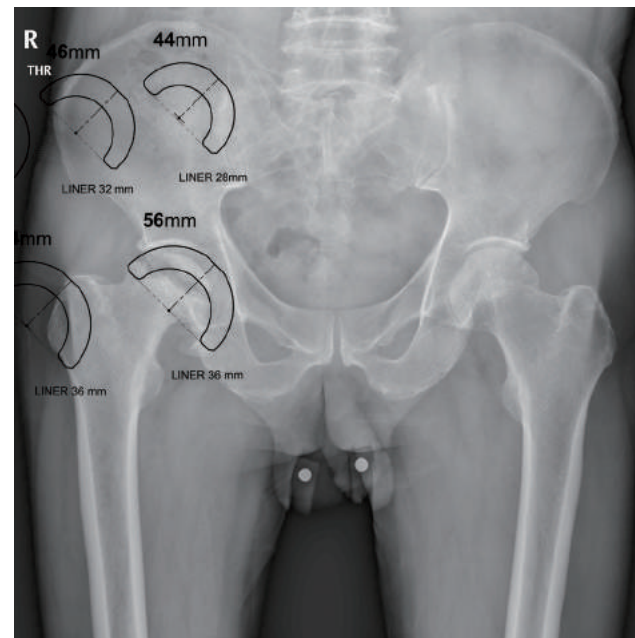
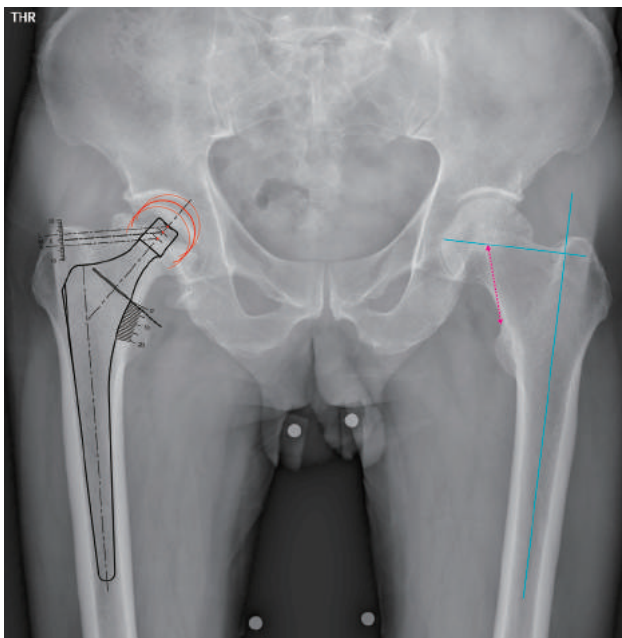
10. Final Reduction & Incision Closure 11



Surgical Technique

I .X-ray Templating: Preoperative Planning

The Bencox II Template System, is designed for the preoperative evaluation of the implant size, offset, and leg length, with the goal of restoring patient's normal anatomy and hip biomechanics. For the preoperative assessment of the component size, templates are generally used on an A/P X-ray of the pelvis, including both hips and a lateral view of the affected hip. X-ray overlays are available in 115% magnification for Bencox II femoral components, and an A/P X-ray/scanogram with 115% magnification in an internal rotation of 10-15°, as needed.(X-ray overlays are available in 100%, 110%, 115%, 120% magnification)



Next, mark the center of rotation of the femoral head on the normal side of preoperative x-ray. Overlay the template onto the A/P X-ray to ensure that the mid-line of the implant is aligned over the anatomical axis of the femoral medullary canal. As the Bencox II stem is a rectangular-shaped stem, unlike a round-corner stem, it should not be measured tightly on the A/P radiograph for stem selection verification.


To reconstruct the normal hip, the head-lesser distance (measure from the head center to the level above the lesser trochanter) can be used as the neck length pre-operatively and intra-operatively. In the case of severe varus or valgus, the difference between the proximal tip of the greater trochanter level, measure the difference in order to determine the center of rotation for the head. To verify the optimum size of the stem & cup, templating directly on the affected hip may be necessary. If "bowing" is evident, lateral view templating is necessary.

Regardless of the osteophyte, the acetabular component should fit with the subchondral bone, and the medial teardrop of the acetabulum.

Surgical Technique

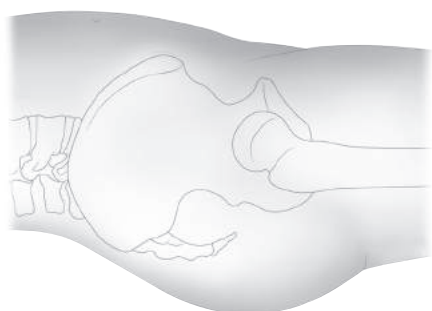
II . Patient Positioning and Surgical Approach

A variety of surgical approaches can be used for the Bencox II Cementless Total Hip System. This protocol indicates the posterolateral and direct-lateral approaches, depending on the surgeon's experience and preference.




1. Posterolateral Approach

In the posterolateral approach, the patient is positioned on his or her side, with the pelvic fixed. The operation site should be exposed by the surgeon.



2. Direct Lateral Approach

In the lateral approach, the patient is made to assume a supine, or full-lateral position.

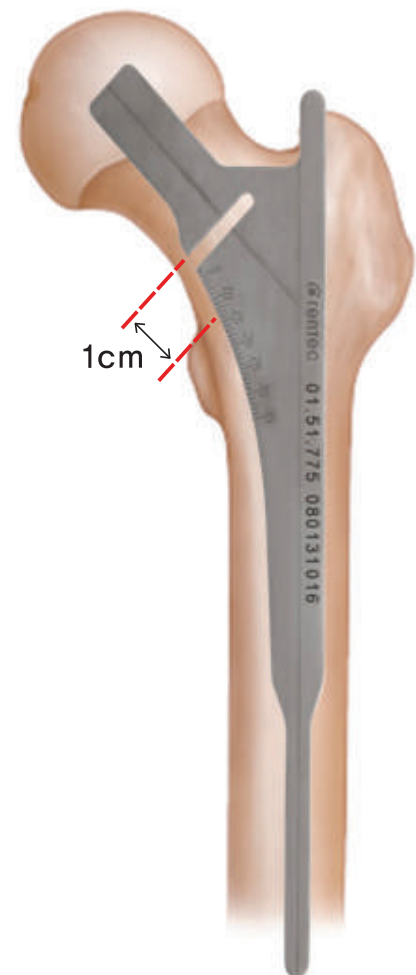


Surgical Technique

III. Surgical Procedures

1. Femoral-Neck Resections

After the exposure of the hip joint via the surgical approach, femoral-neck resection can be carried out, following the gentle dislocation of the femoral head. If dislocation is difficult, the femoral head can be removed using a cork screw after neck resection. Using an oscillating, or a reciprocating saw, femoral-neck resection is recommended at approximately 1-cm above the lesser trochanter, at an angle of 45° from the axis of the femur. Note: The Bencox II Hip System, a collarless system, does not require an exact cutting angle or level.



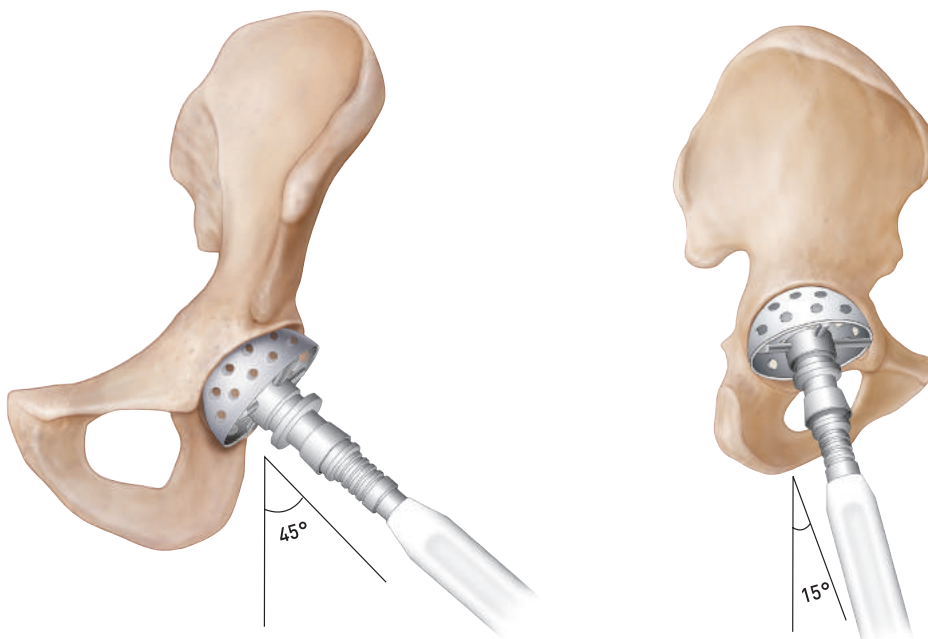
Surgical Technique


2. Acetabular Exposure and Reaming

The acetabular rim must be exposed, and the remains of the capsule must be cleaned. Initiate the reaming with a small, starting reamer to deepen the acetabulum all the way to the medial floor of the acetabular fossa, while at the same time, retaining the subchondral bone in the superior region of the acetabular dome. The whole cartilage should be removed, along with the osteophyte on the acetabular fossa, and the osteophyte on the rim. It is advisable to use reamers in 1-2 mm increments when approaching the definitive acetabular size. During the reaming procedure, hold the reamer in the same direction in which the acetabular cup will be implanted. Clean the acetabulum of all remaining cartilage and soft tissues, down to the bleeding subchondral bone.

3. Positioning of the Acetabular Cup Trialing

The quality of press fit can determine whether the real cup is appropriate, using the trial acetabular cup. It is important to understand that all Bencox Cup system is marked with true dimensions. (54mm trial cup is same as real cup 54mm in diameter)
Insert the 1-2mm bigger size of trial cup than last reamer into the reamed acetabulum. In case of severe osteoporotic bone, may need to insert the 3-4mm bigger size of trial cup than last reamer. Check the stability of the final trial cup. It may be necessary to increase the diameter if the trial cup is unstable.





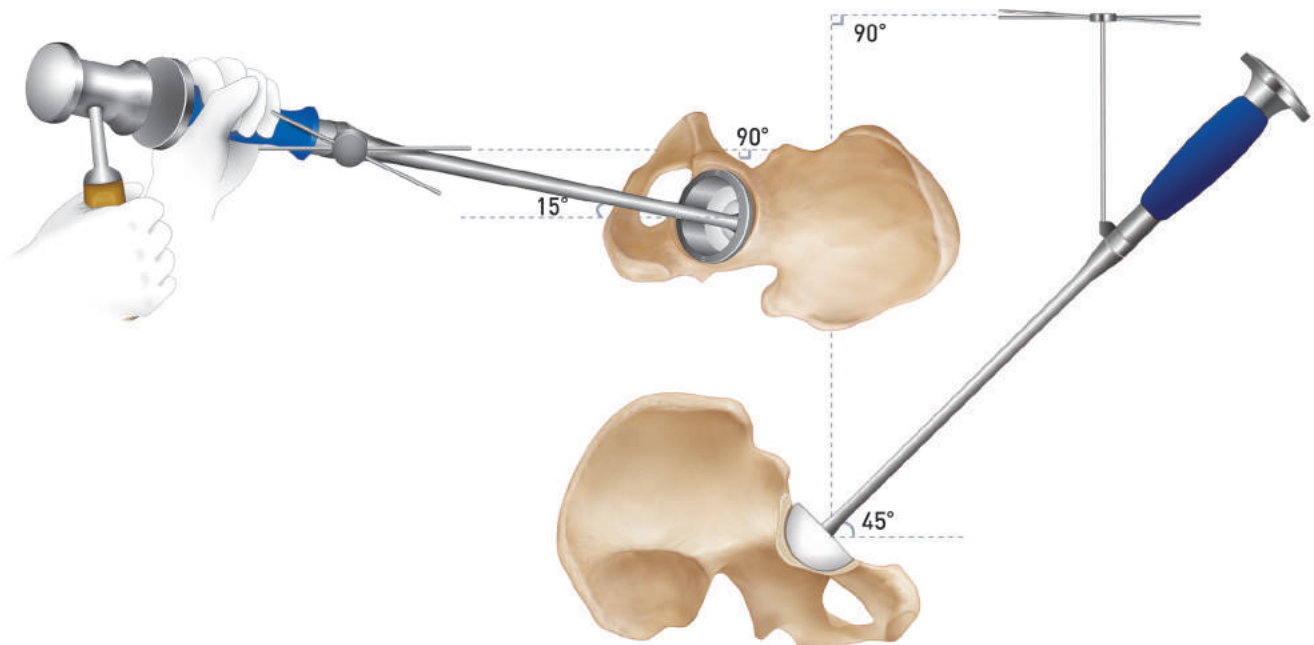
Surgical Technique

4. Positioning and Impacting the Cup

The component is driven in place with the alignment guide positioned over the shaft of the driving instrument, 45° off the patient's vertical axis with 15° anteversion. After the acetabular cup is driven into place and bottoming out has been confirmed, the acetabular cup is again checked to ensure proper orientation.

Extreme care should be taken during placement of the screws in the pelvis to avoid penetrating or piercing vital structures.

After determining the appropriate screw length using a depth gauge, use of one to three screws are suggested, Tighten each screw firmly using a universal screwdriver.



Surgical Technique

5. Liner Insertion

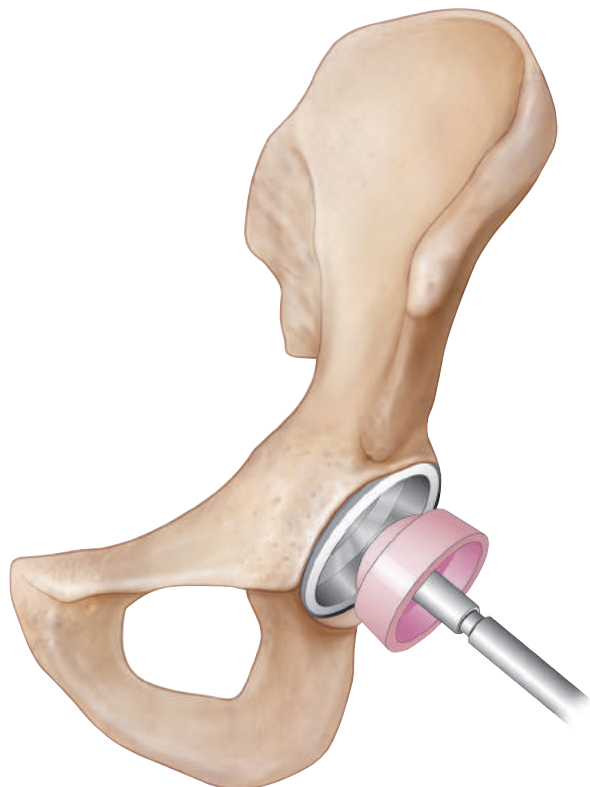
Ceramic or polyethylene Liners are available with internal diameters, including 28, 32, 36, and 40 mm.


Ceramic liner: The ceramic liner is positioned at the bottom of the acetabular metal shell using the ceramic positioner for right-angle insertion. Gently tap the ceramic liner with the liner impactor.

Polyethylene liner: Gently place the polyethylene liner, and adjust its rotation so that the two peripheral slots fit into the metal tab on the acetabular cup. Then fully seat the polyethylene liner with the liner impactor and a gentle mallet blow.

Elevated polyethylene liner: To avoid posterior dislocation, it is recommended that the elevated portion be placed in the posterior acetabulum. The liner can be rotated 30° clockwise or 30° counter clockwise.

Once trial reduction has been used, gently remove the trial acetabular liner and the definitive liner.





Surgical Technique

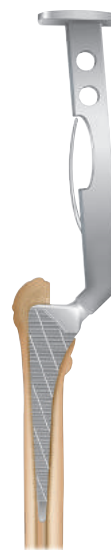
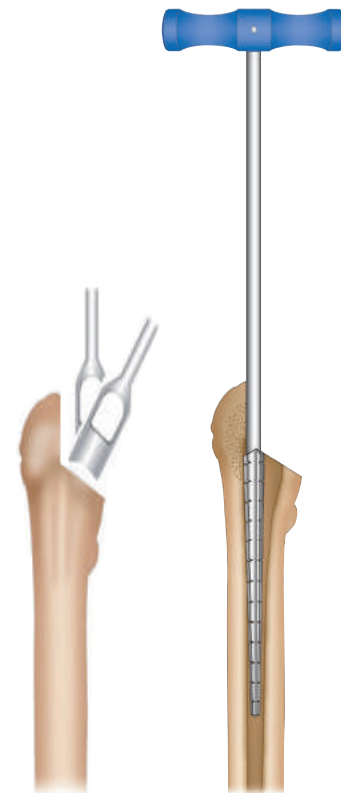
6. Canal Preparation

Open the medullary canal with a Box Chisel at the medial aspect of the greater trochanter. Then insert a Canal Probe and confirm the axis of the femoral medullary canal. Use a the rongeur to remove the bone at the base of the neck at its junction with the greater trochanter so that the stem of the femoral component will not be placed in the varus position.

7. Rasping

Begin the rasping process with the smallest one first. To achieve tight proximal fit, and avoid a varus or valgus position, introduce the Rasps in the same direction as the Canal Probe. Next, drive the rasps into the predetermined neck resection level, taking into account the desired antetorsion (5-10°). As the Bencox II Femoral Stem is rectangular-shaped, which allows for primary stability, perform the rasping gently to minimize the risk of femoral fracture. When the last rasp has been impacted, apply three sizes of the trial head after disassembling to rasp, handle.

Select the appropriate size neck trial corresponding to rasp, the head-lesser distance, or the tip of the greater trochanter.

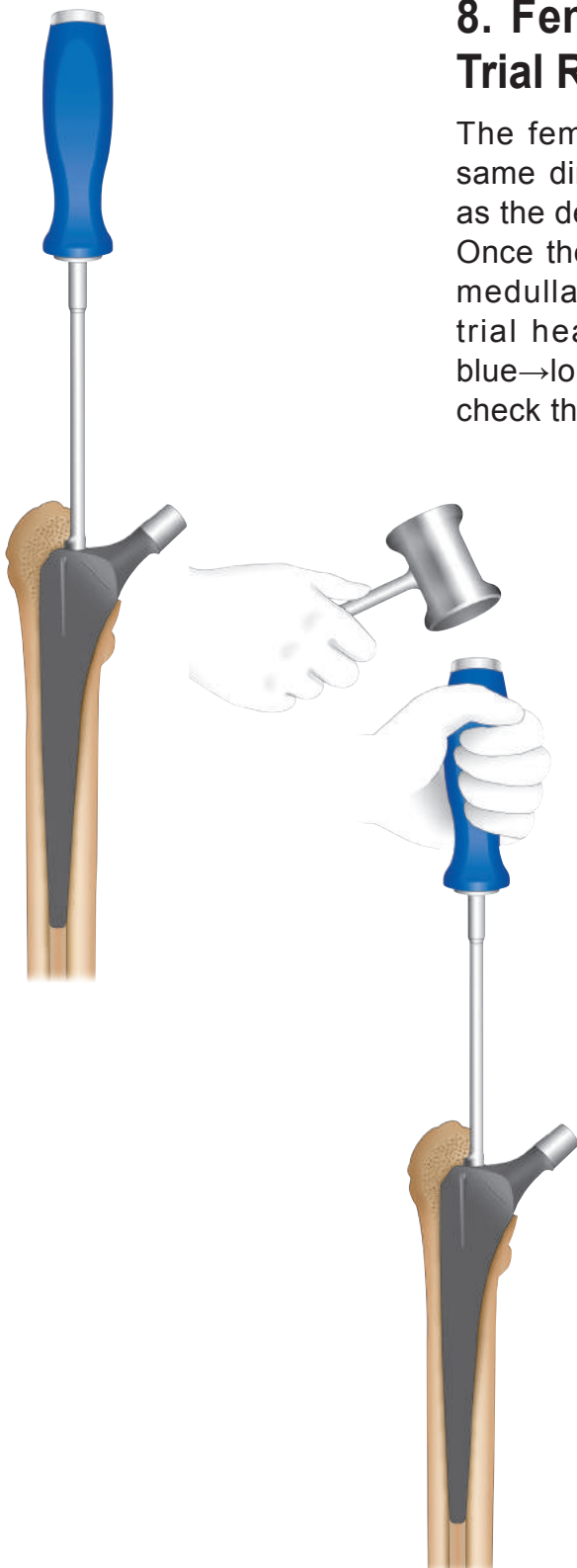



Surgical Technique

8. Femoral Stem Insertion and Trial Reduction

The femoral stem must be inserted in the same direction of rasping in the same level as the determined by rasping.

Once the implant fully seated in the femoral medullary canal. Position the appropriate trial head (gray→short, green→medium, blue→long) of the femoral component. Then, check the range of motion and stability.





Surgical Technique

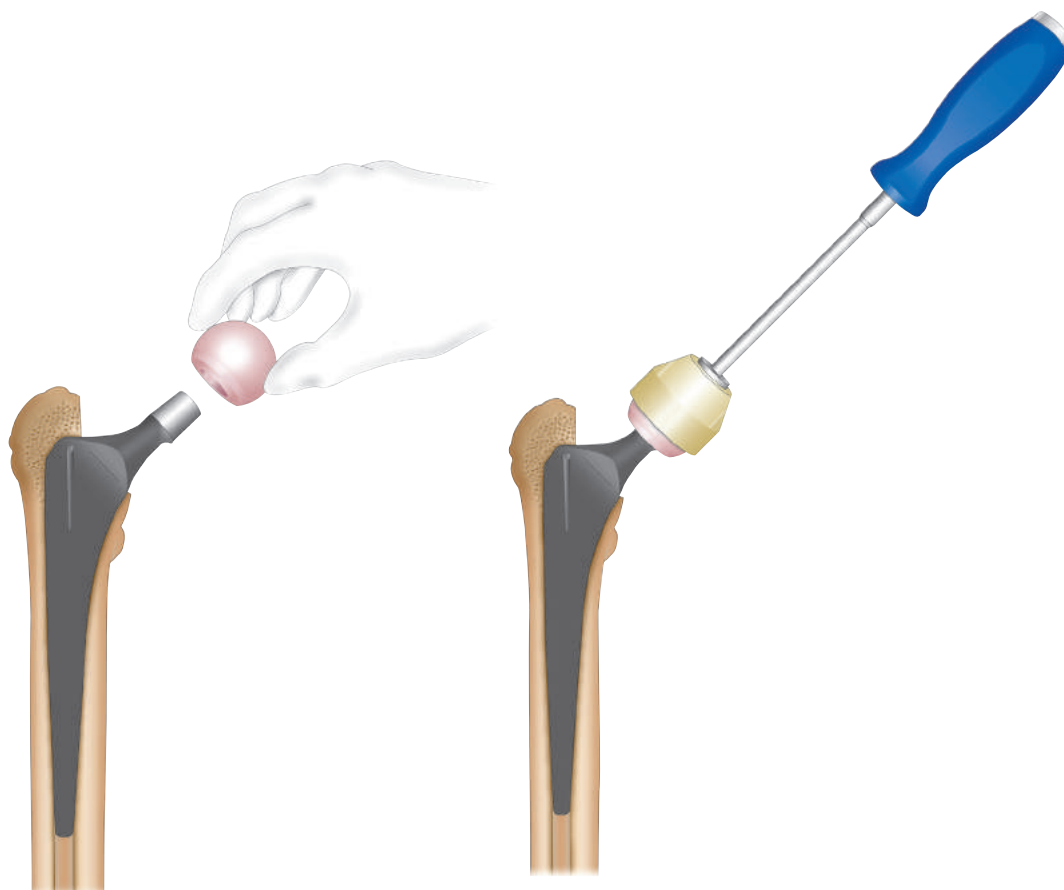
9. Insertion of the Femoral Head

Clean and dry the cone to ensure optimal surface contact. Then place the proper-sized and neck-length femoral head onto the taper of the stem, as determined from the trial reduction.

After reduction, the stability, range of motion and the impingement, should be checked again.

10. Final Reduction & Incision Closure

After the insertion of drainage and closure of the wound.





Manufacturing Plant

12, Yeongsanhong 1-gil, Ipjang-myeon, Seobuk-gu, Cheonan-si, Chungcheongnam-do, Korea
Tel : 82-41-585-7114 Fax : 82-41-585-7113

Seoul Office

483, Gangnam-daero, Seocho-gu, Seoul, Korea
Tel : 82-2-3445-5492~5 Fax : 82-2-3445-5467,5497

Corentec America

7305 Von Karman Ave. Suite 114, Irvine, CA 92614, USA
Tel : 1-949-379-6227 Fax : 1-949-387-5716

 EC Representative

Emergo Europe

Molenstraat
15, 2513 BH, The Hague, The Netherlands
Tel : 31-70-345-8570 Fax : 31-70-346-7299

 **ISO 13485**

www.corentec.com

CAT#CRSC-0100-M07(01)